

Sequential bilateral transplantation in Parkinson's disease

Effects of the second graft

P. Hagell,¹ A. Schrag,⁵ P. Piccini,⁷ M. Jahanshahi,⁶ R. Brown,⁶ S. Rehncrona,² H. Widner,^{1,4} P. Brundin,⁴ J. C. Rothwell,⁶ P. Odin,¹ G. K. Wenning,⁵ P. Morrish,⁷ B. Gustavii,³ A. Bjorklund,⁴ D. J. Brooks,⁷ C. D. Marsden,^{5,6,†} N. P. Quinn⁵ and O. Lindvall¹

¹Division of Neurology and ²Division of Neurosurgery, Department of Clinical Neuroscience and ³Department of Obstetrics and Gynaecology, University Hospital and ⁴Division of Neurobiology, Department of Physiology and Neuroscience, University of Lund, Lund, Sweden and ⁵University Department of Clinical Neurology and ⁶MRC Human Movement and Balance Unit, Institute of Neurology, National Hospital for Neurology and Neurosurgery and ⁷MRC Cyclotron Unit, Hammersmith Hospital, London, UK

Correspondence to: Olle Lindvall, Section of Restorative Neurology, Division of Neurology, Department of Clinical Neuroscience, University Hospital, S-221 85 Lund, Sweden

†Deceased

Summary

Five parkinsonian patients who had received implants of human embryonic mesencephalic tissue unilaterally in the striatum 10–56 months earlier were grafted with tissue from four to eight donors into the putamen (four patients) or the putamen plus the caudate nucleus (one patient) on the other side, and were followed for 18–24 months. After 12–18 months, PET showed a mean 85% increase in 6-L-[¹⁸F]fluorodopa uptake in the putamen with the second graft, whereas there was no significant further change in the previously transplanted putamen. Two patients exhibited marked additional improvements after their second graft: 'on-off' fluctuations virtually

disappeared, movement speed increased, and L-dopa could be withdrawn in one patient and reduced by 70% in the other. The improvement in one patient was moderate. Two patients with atypical features, who responded poorly to the first graft, worsened following the second transplantation. These findings indicate that sequential transplantation in patients does not compromise the survival and function of either the first or the second graft. Moreover, putamen grafts that restore fluorodopa uptake to normal levels can give improvements of major therapeutic value.

Keywords: neural grafting; Parkinson's disease; dopamine; striatum; positron emission tomography

Abbreviations: MPTP = 1-methyl-4-phenyl-1,2,3,6-tetrahydropyridine; UPDRS = Unified Parkinson's Disease Rating Scale

Introduction

Clinical trials with neural transplantation in parkinsonian patients have demonstrated that intrastriatal dopaminergic grafts can survive and induce clinically useful improvements (Lindvall *et al.*, 1990, 1992, 1994; Sawle *et al.*, 1992; Widner *et al.*, 1992; Peschanski *et al.*, 1994; Freeman *et al.*, 1995; Remy *et al.*, 1995; Defer *et al.*, 1996; Wenning *et al.*, 1997). If ventral mesencephalic tissue from three or more 6- to 9-week-old human embryos is implanted into the putamen, positron emission tomography (PET) studies consistently

show increased 6-L-[¹⁸F]fluorodopa uptake (Lindvall *et al.*, 1990, 1992, 1994; Sawle *et al.*, 1992; Widner *et al.*, 1992; Freeman *et al.*, 1995; Remy *et al.*, 1995; Wenning *et al.*, 1997). Histopathological studies (Kordower *et al.*, 1995, 1996, 1998) have confirmed that the increased fluorodopa uptake seen in PET studies reflects the survival of dopaminergic grafts reinnervating the patient's striatum. After a delay of at least 2–3 months, a majority of patients with surviving grafts have developed a typical pattern of improved

motor function with increased duration of the L-dopa effect and time in the 'on' phase, and reduced severity of rigidity and hypokinesia in the 'off' phase (Freeman *et al.*, 1995; Defer *et al.*, 1996; Wenning *et al.*, 1997).

Although the evidence for graft survival and function in patients with Parkinson's disease is now solid, it is also clear that functional recovery is incomplete both in terms of magnitude and the pattern of improvement. It is conceivable that this at least partly reflects the fact that in most operated patients only a minor portion of the dopamine-denervated striatum has been reinnervated by the grafts. In such cases, patients have been transplanted either unilaterally (Defer *et al.*, 1996; Wenning *et al.*, 1997) or bilaterally but only in the posterior putamen (Freeman *et al.*, 1995). Alternatively, implant sites have been few (Defer *et al.*, 1996; Wenning *et al.*, 1997), and no good evidence for graft survival in the caudate has been obtained using PET (Remy *et al.*, 1995; Wenning *et al.*, 1997).

It is well established that unilateral grafts can induce bilateral improvements in patients with Parkinson's disease (Lindvall *et al.*, 1990, 1992, 1994; Defer *et al.*, 1996; Wenning *et al.*, 1997), but there is a good case for bilateral implants in order to effect long-term, more complete recovery of motor function. First, the improvement after unilateral transplantation is most marked on the side of the body contralateral to the graft (Defer *et al.*, 1996; Wenning *et al.*, 1997), which implies that a second graft should result in clinical benefit additional to that conferred by the first. Secondly, in idiopathic Parkinson's disease there is an ongoing degeneration of the patient's own dopaminergic neurones which is not itself retarded by the implantation of embryonic mesencephalic tissue. The degenerative process therefore leads to a progressive worsening of parkinsonian symptoms primarily ipsilateral to a unilateral graft. Thirdly, axial symptoms, speech, gait and dyskinesias, which are neither consistently nor markedly improved by unilateral grafts (Wenning *et al.*, 1997), may be influenced only by bilateral implants. In fact, all patients with reported clear reduction of dyskinesias have been grafted bilaterally in the putamen (Widner *et al.*, 1992; Freeman *et al.*, 1995).

Bilateral transplantation of embryonic tissue might, however, be associated with a greater risk of adverse effects compared with unilateral implantation. In addition to increased risk of perioperative haemorrhage, the larger number of surgical trajectories induces increased tissue trauma, which might cause motor or cognitive dysfunction. Immunological mechanisms could be particularly important with sequential, bilateral implants. With a large number of donors, there is a risk that mesencephalic tissue with similar transplantation antigens is implanted in sequence. This might lead to graft rejection unless immunosuppressive treatment is given.

In a previous paper (Wenning *et al.*, 1997), we described PET findings and clinical and neurophysiological data following unilateral transplantation to the putamen alone (four cases) or putamen plus caudate nucleus (two cases) in

six patients (patients 3, 4 and 7–10 in our series). Here we report the findings after subsequent grafting to the other side in five of these patients (patients 3 and 7–10). A summary on the other patients (patients 1, 2 and 4–6) in our series is also provided in the Appendix. The objectives were two-fold: first, to explore the possibility that a second transplantation can influence the survival and function of the first or second graft; and secondly, to clarify whether the second graft leads to further clinical improvement and, if this is the case, a different pattern of recovery compared with the first graft.

Methods

Grafting procedure

The patients' consent was obtained according to the declaration of Helsinki and the procedures were approved by the local ethical committees in Lund (Research Ethics Committee, Lund University) and London (The National Hospital for Neurology and Neurosurgery and the Institute of Neurology Joint Medical Ethics Committee, and Imperial College School of Medicine/Hammersmith, Queen Charlotte's & Chelsea and Acton Hospitals Research Ethics Committee). On entry to the study, prior to their first graft, and also prior to their second graft, all patients fulfilled the United Kingdom Parkinson's Disease Brain Bank criteria for idiopathic Parkinson's disease (Gibb and Lees, 1988). The patients had received unilateral grafts either in the putamen alone or in both the putamen and the caudate nucleus (Table 1; for details of procedure and postoperative follow-up, see Lindvall *et al.*, 1989; Rehncrona, 1997; Wenning *et al.*, 1997). Briefly, implantation of embryonic mesencephalic tissue on the non-operated side was performed in Lund using CT-guided stereotaxic neurosurgery. In all patients (Table 1), grafts were placed in the putamen along five trajectories in the ventrodorsal direction. Patient 8 was also grafted similarly along two trajectories in the head of the caudate nucleus on the same side. Dissociated ventral mesencephalic tissue from four to eight aborted human embryos (aged 6–8 weeks post-conception; crown–rump length 13–27 mm) was implanted in each patient. Twenty microlitres of cell suspension was deposited in each putaminal trajectory, each of which was 12–14 mm long. The trajectories were planned to optimize the reinnervation of the putamen. The maximal distance between adjacent transplantation sites was 5–8 mm in the anteroposterior direction, the distance between the most anterior and posterior sites ranging from 22 to 29 mm. The caudate trajectories were 14 mm long and placed 4 mm apart. All patients had received immunosuppressive therapy using a standard regimen of cyclosporin, azathioprine and prednisolone from the time of the first transplantation (Lindvall *et al.*, 1989). Apart from patients 3 and 8 (azathioprine discontinued at 20 and 6 months, respectively), this regimen was kept constant throughout the follow-up period.

Table 1 Characteristics of patient group

Patient	Hoehn and Yahr*	Years of transplantations	Age/disease duration/duration of L-dopa therapy (years) [†]	Location of implants**	No. of donors**	Follow-up (months)**	Daily L-dopa dose (mg): preop [‡] /postop [‡]
3 (Lund)	3	1989, 1993	53/16/15	L put/R put	4/5	80/24	700/800
7 (London)	2	1993, 1994	50/11/10	L put/R put	5/5	41/24	200/0
8 (London)	4	1993, 1995	45/7/7	L put + caud/ R put + caud	5/8	41/18	500/300
9 (Lund)	4	1993, 1994	53/11/9	L put/R put	4/7	29/18	950/750
10 (London)	4	1994, 1994	43/13/11	R put + caud/L put	7/4	34/24	850/300

*In practically defined off phase, prior to the first graft; **for the first/second graft; [†]at the time of the second grafting; [‡]at the end of follow-up period. L-dopa was given with a peripheral decarboxylase inhibitor. L = left; R = right; put = putamen; caud = caudate nucleus; preop = preoperatively; postop = postoperatively.

Methods of assessment

The CAPIT (Core Assessment Program for Intracerebral Transplantations) (Langston *et al.*, 1992) was followed. Detailed descriptions of the clinical evaluation programme, single-dose L-dopa test, laboratory measurements of simple arm and hand movements (performed at the Medical Research Council Human Movement and Balance Unit in London) and 6-L-[¹⁸F]fluorodopa PET studies (performed at the MRC Cyclotron Unit in London) are provided elsewhere (Lindvall *et al.*, 1989; Langston *et al.*, 1992; Sawle *et al.*, 1992; Widner *et al.*, 1992). Throughout the entire protocol, from baseline assessments before the first graft until the latest assessments after the second graft, in each centre two evaluators only were responsible for patient ratings.

Results

General clinical course and assessment of motor function

Patient 3

This patient was grafted in the left putamen in 1989 (Table 1). Postoperatively, he showed reduced time in the off phase, a longer duration of the L-dopa effect and less severe rigidity and hypokinesia during the off phase bilaterally, but predominantly on the side contralateral to the graft. From 27 months after grafting, his parkinsonian symptoms worsened with increased rigidity and hypokinesia on the side ipsilateral to the first graft, whereas continued improvement was observed on the contralateral side (Lindvall *et al.*, 1990, 1992, 1994; Wenning *et al.*, 1997).

He was grafted in the right putamen in 1993 (Table 1). From the second postoperative month, he noted longer periods in the on phase and improved function in the left arm, which became better than the right arm. Autoscoring (on-off diaries) revealed a moderate decrease in time spent in the off phase during the first but not the second postoperative year (Table 2). Mild, rare on-phase dyskinesias, which had not been observed preoperatively, appeared. There was a modest reduction in the off-phase Unified Parkinson's Disease Rating Scale (UPDRS) motor score (Fig. 1). The duration of the

effect of a single L-dopa dose was similar to that observed before the second transplantation (Table 2). Off-phase rigidity disappeared and timed motor tasks improved slightly contralaterally to the second graft (Figs 2 and 3).

As indicated by UPDRS scores during practically defined off phase (data not shown), the second graft did not induce any consistent improvements in his gait, swallowing or posture, while speech deteriorated slightly.

Eleven months after transplantation, bromocriptine was discontinued because of pleuropulmonary inflammation. After 13 months, the patient started to experience right-sided, painful, off phase-related L-dopa-responsive dystonia. However, his on phases were still good. Secondarily to multiple degenerated cervical discs, he developed a radiculopathy affecting the right hand and arm 22 months after transplantation. Hand and arm function became severely impaired and regular assessments were therefore stopped at 24 months. Dystonias subsequently improved on a combination of amantadine and ropinirole.

Daily living was clearly improved in this patient following transplantation. Activities became easier and he was able to perform independently. Although this was later compromised by dystonia, progressive back problems and peripheral paresis of the upper right extremity, he still experiences valuable improvement of his underlying parkinsonism.

Patient 7

This patient was grafted in the left putamen in 1993 (Table 1). Following transplantation, the UPDRS motor score and time spent in the off phase decreased and the L-dopa effect was prolonged. There was a marked reduction in rigidity in the contralateral arm and motor function improved bilaterally, but predominantly contralaterally to the graft (Wenning *et al.*, 1997).

In 1994, he received a second graft in the right putamen (Table 1). Postoperatively, the patient reported improvement of off-period akinesia and on-period dyskinesia. Arm swing returned on the left side ~2 months after transplantation and turning in bed became easier. At 8 months, the patient

Table 2 Autoscored mean percentage of awake time spent in the off and on phases with dyskinesias* and duration of the on phase induced by a single dose of L-dopa**

Patient	Preoperative [†]		Postoperative (second graft)		
	First graft	Second graft	Months 1–6	Months 7–12	Months 13–24
3					
Percentage of time in off phase	50.2 ± 1.3	28.5 ± 1.5	21.0 ± 1.8	19.7 ± 1.6	29.0 ± 1.6
Percentage of time in on phase with dyskinesias	0	0	2.9 ± 1.4	1.1 ± 0.7	1.4 ± 0.6
Duration of on phase after a single L-dopa dose (min)	105 (90–120; 4)	195 (195–195; 3)	238 (195–285; 5)	189 (135–210; 5)	180 (135–210; 3)
7					
Percentage of time in off phase	24.3 ± 3.9	10.5 ± 5.8	3.8 ± 1.3	2.4 ± 2.0	0
Percentage of time in on phase with dyskinesias	29.7 ± 3.4	13.7 ± 5.4	9.5 ± 4.2	0.9 ± 1.1	0
Duration of on phase after a single L-dopa dose (min)	116 (99–137; 6)	146 (125–180; 5)	139 (97–195; 4)	185 (130–240; 2)	256 (205–375; 6)
8					
Percentage of time in off phase	43.1 ± 3.8	32.0 ± 12.7	25 [‡]	30 [‡]	30 [‡]
Percentage of time in on phase with dyskinesias	31.3 ± 3.9	50.5 ± 6.4	75 [‡]	0 [‡]	5 [‡]
Duration of on phase after a single L-dopa dose (min)	129 (74–222; 4)	191 (185–197; 2)	153 (150–156; 2)	89 (70–125; 4)	111 (100–135; 4)
9					
Percentage of time in off phase	20.8 ± 3.4	6.6 ± 1.1	24.1 ± 2.1	6.9 ± 2.8	32.0 ± 2.9
Percentage of time in on phase with dyskinesias	18.9 ± 6.5	54.3 ± 1.8	63.5 ± 2.3	23.4 ± 3.9	2.7 ± 1.1
Duration of on phase after a single L-dopa dose (min)	85 (45–120; 6)	110 (60–165; 6)	150 (135–175; 4)	188 (150–225; 4)	184 (165–210; 4)
10					
Percentage of time in off phase	51.8 ± 1.9	23.4 ± 9.9	47.7 ± 8.6 [§]	No longer able to distinguish on from off	
Percentage of time in on phase with dyskinesias	45.8 ± 4.5	47.2 ± 33.8	4.3 ± 9.0 [§]		
Duration of on phase after a single L-dopa dose (min)	127 (85–223; 5)	186 (160–205; 4)	274 (195–420; 3)	238 (110–365; 2)	267 (240–300; 6)

*Values are given as mean ± 95% confidence interval; **values are given as mean (range; number of tests); [†]data from assessments during the last 6 months prior to the first and second transplantation are included; [‡]patient 8 was not able to keep reliable on/off diaries, but approximate overall estimates made by his carer, wife and research physician are given; [§]data from assessments during the first 3.5 months after the second transplantation; from the fourth postoperative month he did not keep on/off diaries due to difficulties distinguishing between off and on phases.

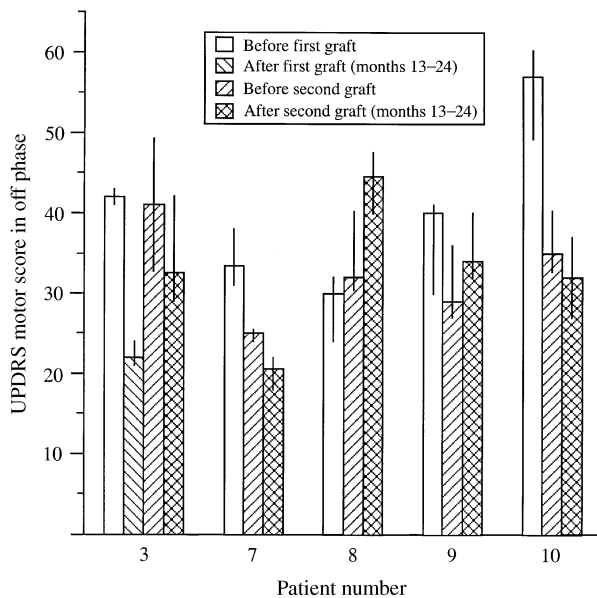


Fig. 1 Scores from the motor examination part of the Unified Parkinson's Disease Rating Scale (UPDRS) (items 18–31, maximum score = 108) in the practically defined off phase. Data are from assessments performed during the 6 months prior to each transplantation and during the second year following the second graft. Due to the long interval between the transplantations in patient 3 (56 months), data from the second postoperative year after the first graft are also included for this patient. Data are median ± 25th percentile.

stopped taking L-dopa due to a slight increase in dyskinesias, but remained on pergolide, amantadine and selegiline, with reduced dyskinesias. Off periods virtually disappeared and he no longer experienced on–off fluctuations. Left arm function improved to become as good as that of the right arm. However, his gait was slow and hampered by dystonia

of the right leg, but this has steadily improved. Selegiline was withdrawn after 17 months without deterioration.

Autoscoring revealed a gradual disappearance of off periods, despite withdrawal of L-dopa and selegiline, and of on periods with dyskinesias (Table 2). Prolongation of the duration of the on phase induced by a single dose of L-dopa was consistent with these changes (Table 2). Also, the UPDRS motor score in the off phase was modestly reduced during the second postoperative year (Fig. 1) and the performance of timed motor tasks was further, moderately, improved contralaterally, and modestly improved ipsilaterally to the second graft (Figs 2 and 3).

Postural stability, swallowing and gait during the off phase, which were normal or slightly impaired preoperatively, did not change after the second graft (data not shown). There was mild deterioration of posture but some improvement of dysarthria and hypophonia.

This patient is now running his own business on a full-time basis (he previously worked part-time), and has also been able to take up car-driving again, which was impossible before surgery. Other activities of daily living, although not impossible previously, have become easier to perform.

Patient 8

This patient was grafted in the left putamen and caudate nucleus in 1993 (Table 1). He showed modest improvement of some motor symptoms, but his UPDRS motor score increased after grafting, mainly due to deterioration of axial features (Wenning *et al.*, 1997). Because of impotence, progressive urinary symptoms and a change from normal (preoperative) to pathological anal sphincter EMG, a diagnosis of multiple system atrophy was suspected (Wenning *et al.*, 1997), but this remains unproven.

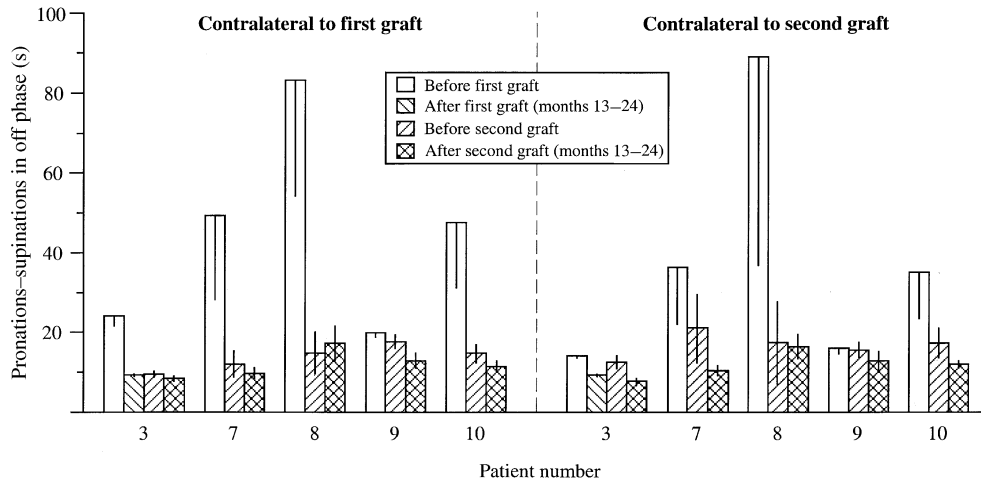


Fig. 2 Time to perform 20 pronations-supinations with the arm contralateral to the first and second grafts, respectively, during the practically defined off phase. Data are from assessments performed during the 6 months prior to each transplantation and during the second year following the second graft. Due to the long interval between the transplantations in patient 3 (56 months), data from the second postoperative year after the first graft are also included for this patient. Data are mean \pm 95% confidence interval.

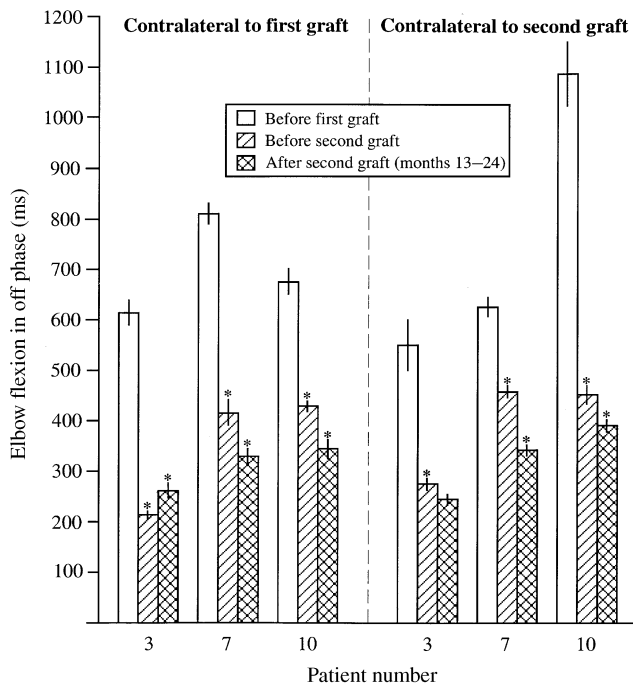


Fig. 3 Performance of simple arm movements (elbow flexion alone) contralateral to the first and second grafts during the practically defined off phase, as assessed using EMG. Data are mean \pm SEM. Statistical comparisons were made between the measurements before the first and the second graft, and between measurements before and after the second graft. * $P < 0.05$, Student's *t* test.

In 1995, he received a second graft in the right putamen and caudate nucleus (Table 1). About 2 months after surgery, the time spent in the on phase increased and was associated with more dyskinesias on the left side. L-Dopa was withdrawn 3.5 months postoperatively and he was then treated only with pergolide and selegiline. Dyskinesias decreased and he had

a good response throughout the day, with more benefit on the left than on the right side. His arms were more improved than his legs and his gait remained impaired.

Seven months postoperatively the patient was admitted because of depression with paranoia. Following withdrawal of pergolide and selegiline, his mental status improved but he became markedly akinetic. He was discharged on amantadine and an antidepressant, and spent most of the day in an intermediate state. At 11 months, a small dose of L-dopa was restarted and benzhexol hydrochloride was introduced due to off-phase dystonia, but off periods did not improve. Despite this general deterioration, arm function and rigidity on both sides remained improved compared with the situation prior to the first graft (Fig. 2).

Neurological assessment demonstrated further overall deterioration after the second transplantation. The UPDRS motor score increased (Fig. 1) and the on-duration after a single dose of L-dopa became shorter (Table 2). Speech and gait deteriorated, whereas postural stability, posture and swallowing were unchanged (data not shown).

The assessment of this patient was complicated by his depression and psychosis, and the reduction of anti-parkinsonian medication. However, our clinical impression, as well as that of his carers, is that despite an improvement in hand function that enabled him to perform manual tasks better, there has been an overall deterioration from his preoperative state.

Patient 9

This patient was grafted in the left putamen in 1993 (Table 1). He showed only modest improvement in motor function (Wenning *et al.*, 1997).

He was grafted in the right putamen in 1994 (Table 1).

Prior to the onset of Parkinson's disease, he had been treated for hypertension. After the second transplantation, the patient again developed hypertension, which was treated with nifedipine and atenolol. From the fifth postoperative month, his condition transiently improved and the time spent off and on with dyskinesias decreased. During the following months, his daily activities improved and he was able to work in the garden and repair his house. At 11 months, dyskinesias increased and L-dopa was gradually reduced. One month later, his motor performance worsened and was complicated by dyspraxia, which sometimes interfered with motor tests.

There had already been some evidence of cognitive impairment before the first graft (Mini-Mental State Examination score: 25/30). Following the second transplantation, this patient's cognitive status deteriorated rapidly. In addition to memory loss, he developed confusion, visual hallucinosis, anxiety, restlessness and insomnia. He underwent a change in personality, and became disoriented in time and sometimes also in space. Selegiline (10 mg/day) and orphenadrine (100 mg/day) were withdrawn without any obvious effects on his cognitive status. Neuropsychological assessment confirmed a cortical dementia. Regular clinical assessments were discontinued at 18 months due to difficulties with compliance.

Autoscoring suggested a gradually increased time in the off phase and decreased time in the on phase with dyskinesias during the second year after transplantation (Table 2). However, due to cognitive impairment, the data from the second postoperative year should be interpreted cautiously. The on-phase duration following a single dose of L-dopa lengthened (Table 2) whereas the UPDRS motor score increased (Fig. 1). Timed motor tasks showed a modest improvement (Fig. 2) but rigidity was virtually unchanged. Gait, postural stability and posture deteriorated (data not shown).

Twenty-five months after the second graft, the patient died due to a massive intracerebral haemorrhage ipsilateral to the first graft, performed 36 months earlier. The haemorrhage probably emanated from the thalamic region. Autopsy of his brain could not be performed.

Patient 10

In 1994, this patient was transplanted in the right putamen and caudate nucleus (Table 1). Postoperatively, the L-dopa effect was prolonged and he spent more time in the on phase. The UPDRS motor score decreased and there was a marked bilateral, but predominantly contralateral, increase in movement speed in the arms during the off phase (Wenning *et al.*, 1997).

Ten months after the first implantation, he was grafted in the left putamen (Table 1). Already 1 month before surgery, dyskinesias had increased and were present on the left side even during the off phase. Two weeks after grafting, he was admitted because of severe, almost continuous dyskinesias. He had stereotypic trunk and leg flexion movements and intermittent, choreodystonic involuntary movements of the

left limbs. The daily L-dopa dose was reduced and dyskinesias improved markedly. At 3 months he reported qualitative improvements of off periods and activities of daily living. Dyskinesias were continuous but only mild. Four to five months after transplantation, stereotyped, non-disabling movements with the right hand touching the ipsilateral hip developed, whereas stereotypic movements of the left arm, which had been present before the second graft, subsided. Gait and freezing improved, and the number of falls (due to freezing) decreased from up to 15 to about six per day. Right arm function improved and since then he has preferred to use the right hand. Due to increased dyskinesias at 7 months, the L-dopa dose was gradually reduced and dyskinesias subsequently decreased. Other medications, i.e. amantadine (200 mg/day) and selegiline (10 mg/day), remained unchanged from those administered before the first graft.

Autoscoring was discontinued by the patient 3.5 months after the second graft due to difficulties in differentiating between the on and off phases. However, very brief periods (ranging from a period of seconds to 5 min) of dyskinesias as well as mild off phases did occur thereafter. The on duration after a single dose of L-dopa lengthened (Table 2), while the UPDRS motor score (Fig. 1) and rigidity in the off phase were virtually unchanged. Timed motor tasks were performed more rapidly (Figs 2 and 3).

Overall, this patient had definite clinical benefit following grafts. Following the first one, he became able to walk independently in either the on or the off phase and to perform activities of daily living such as dressing and eating independently. After the second graft there was marked improvement in ease of movements, especially walking, despite a major L-dopa reduction. On the other hand dysarthria, hypophonia and chewing showed progressive deterioration.

Assessment of graft survival

Regional [¹⁸F]fluorodopa influx rate constant (K_i) values in the caudate nucleus and putamen, as defined by using the multiple time graphical analysis method with occipital reference tissue as the input function, before and after the first and second transplantations are shown in Fig. 4. Only data from scans after the second graft will be described here; other findings have been reported previously (Sawle *et al.*, 1992; Lindvall *et al.*, 1994; Wenning *et al.*, 1997).

Scans from all patients showed elevated levels of fluorodopa uptake (K_i) in the grafted putamen 12–18 months after surgery compared with the last scan prior to the second transplantation. The increase ranged from 49% in patient 3 to 139% in patient 10, the mean for the whole group being 85%. In the contralateral putamen, which had shown increased fluorodopa uptake after the first transplantation in all patients, the changes after the second graft were only minor. In three patients, the K_i value was unchanged (+1 to 3%) and in two patients there was a modest decrease (by 20 and 22%), so that the overall fluorodopa uptake decreased in the first grafted putamen by a mean of 7% after the second graft.

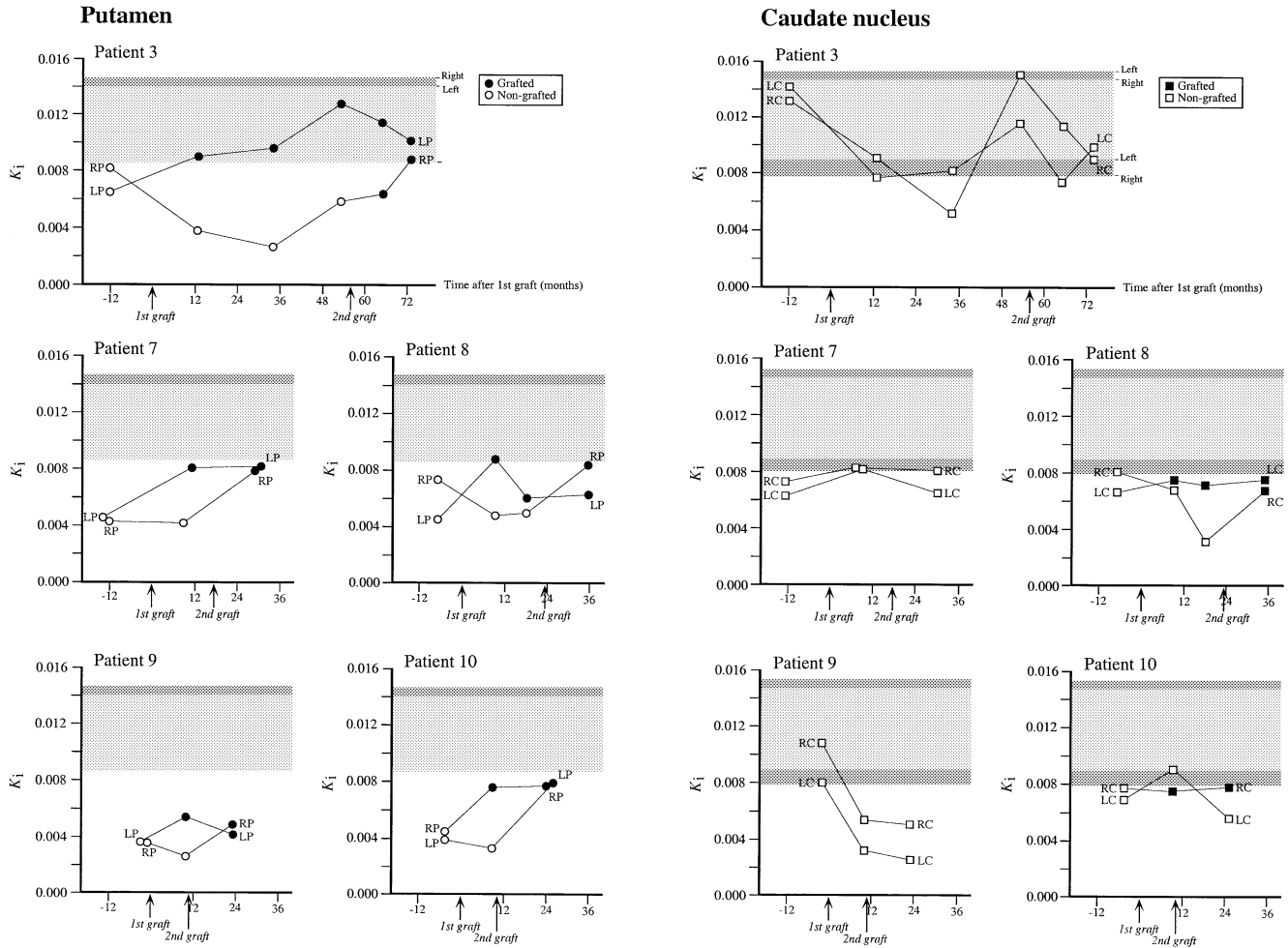


Fig. 4 Regional [¹⁸F]fluorodopa uptake (K_i) after sequential, bilateral transplantation of embryonic mesencephalic tissue to the putamen and caudate nucleus in patients 3 and 7–10. Comparative data are given for a group of 17 healthy volunteers. The shaded area illustrates the normal mean minus two standard deviations. The upper darker fields depict the means on the left and right side; the lower darker fields represent the values two standard deviations below the mean in the left and right caudate nucleus. Numbers on the x axis refer to months before (minus) and after the initial transplantation. The data before the second graft have been reported previously (Wenning *et al.*, 1997). The K_i value obtained at 53 months in patient 3 should be interpreted cautiously since this measurement was associated with a lot of head movement. RP = right putamen; LP = left putamen; RC = right caudate nucleus; LC = left caudate nucleus.

The caudate nucleus that had not been implanted with embryonic tissue showed a mean 20% increase in fluorodopa uptake (at 12–18 months), whereas there was virtually no change in the previously grafted caudate nucleus in patients 8 and 10 (+6 and 4%, respectively). Only patient 8 received implants in the caudate nucleus at the second transplantation. Although there was a 112% increase in fluorodopa uptake, this change should be interpreted cautiously because the last value before transplantation was very low. If the value prior to the last value was used for comparison, no change was detected.

Discussion

Survival of first and second grafts

The present findings provide further evidence that implantation of embryonic ventral mesencephalic tissue into

the striatum of parkinsonian patients leads to highly reproducible survival of dopamine neurons. Twelve to eighteen months after surgery, all patients showed significantly increased fluorodopa uptake in the grafted putamen. When comparing the changes in putaminal fluorodopa uptake after the second transplantation with those observed after the first grafting (Wenning *et al.*, 1997), two major conclusions can be drawn. First, previous successful transplantation of human embryonic tissue does not interfere with the survival and growth of dopamine neurons implanted 10–56 months later on the other side. The mean increase in fluorodopa uptake in the present five patients 12–18 months after the second graft (85%) was thus similar to that 8–12 months after the first graft (68%) (Wenning *et al.*, 1997). Secondly, implantation of a second graft does not interfere with the survival of a well-developed first graft on the contralateral side. Only minor changes in fluorodopa uptake occurred in

the putamen containing the first graft after the second transplantation.

These findings are in good agreement with previous observations, made after sequential grafting of embryonic mesencephalic tissue in non-immunosuppressed animals. However, it should be noted that the patients in the present study were on chronic immunosuppression, partly to allow retransplantation after long time intervals. Widner and Brundin (1993) and Duan *et al.* (1993) grafted allogeneic nigral tissue to the striatum of rats in two sessions, with the two graft surgeries separated in time by 15 and 8 weeks, respectively. They reported no differences in graft size when comparing the survival of the first and second implants, despite the allogeneic donor–host combination. However, there was a moderate increase in MHC (major histocompatibility complex) class II expression on microglia-like cells in and around the second graft (Duan *et al.*, 1993). Similarly, Kordower and colleagues (Kordower *et al.*, 1997) reported that well-developed intraputamenal dopaminergic grafts contained numerous microglia, macrophages and T and B cells in two patients with Parkinson's disease who died 18–19 months after transplantation of human embryonic tissue. These patients were grafted bilaterally at a 4-week interval and were given cyclosporine for 6 months thereafter, but no steroids. Thus, there is a potential for immune reaction against the graft, which might compromise its viability and function. Nevertheless, in our patients no evidence has so far been obtained for immunological rejection up to 6 years after the first transplantation (Wenning *et al.*, 1997) or up to 2 years after the second transplantation.

Magnitude of functional effects after first and second grafts

Three patients had already experienced clinically useful symptomatic relief after the first graft. Two of them (patients 7 and 10) showed further marked improvements whereas one patient (patient 3) exhibited only moderate improvement after the second graft. The two patients (patients 8 and 9) who had only minor functional effects after the first implantation worsened following the second transplantation. As discussed previously, patient 9 developed cortical dementia. Patient 8 exhibited an atypical clinical picture that raised the suspicion of multiple system atrophy (Wenning *et al.*, 1997). He also developed an episode of depression and paranoia after the second transplantation that necessitated a reduction in anti-parkinsonian medication, which makes direct comparison with his preoperative state difficult. Although he had a negative psychiatric history, there was a positive family history of depression. Taking all these factors into account, we consider it unlikely that this development was a result of the graft. The lack of long-term major symptomatic relief in this patient, whose fluorodopa uptake in the grafted putamen reached a level similar to those in patients 3, 7 and 10, may be explained by the atypical nature of his parkinsonism.

The clinical course in patient 9 was complicated by the development of additional pathology, which may have compromised the beneficial effects of the second graft. Neither patient 8 nor patient 9 exhibited any signs indicating atypical disease development, clinically or on the preoperative PET scans. These patients illustrate both the difficulty and the importance of patient selection in neural transplantation trials. Although the present series of patients is too small to draw any firm conclusions, it indicates that patients with cognitive impairments or atypical features are less likely to gain clinically significant therapeutic benefit from neural grafting according to the present protocol.

The magnitude of functional recovery in patients 3, 7, 9 and 10 broadly corresponds with the degree of restoration of putamenal fluorodopa uptake. The fluorodopa uptake in the grafted putamen of the patients exhibiting marked or moderate symptomatic relief (patients 3, 7 and 10) had increased to a level within or close to two standard deviations below the mean putamenal uptake in healthy volunteers (Fig. 4). Patient 9 had only modest clinical effects after grafting, and fluorodopa uptake remained much lower than normal despite a postoperative increase (Fig. 4). We have previously shown restoration of fluorodopa uptake to the normal mean in the unilaterally grafted putamen of patient 4, who had excellent recovery and was able to manage without L-dopa treatment for 3.5 years (Wenning *et al.*, 1997; Appendix). Furthermore, in the whole series of six patients (numbers 3, 4 and 7–10), the global clinical outcome (as indicated by the clinical outcome scores in Table 3) exhibits a statistically significant correlation with the percentage increase in putamenal fluorodopa uptake, when comparing the last postoperative PET scan with the preoperative scan (mean of the two sides; Spearman's rank correlation coefficient = 0.971, $P = 0.0299$).

It is conceivable that the rate of degeneration of the patient's own nigrostriatal dopamine system also influences the clinical evolution after transplantation. In the whole series (patients 3, 4 and 7–10), the mean annual rate of decrease in putamenal fluorodopa uptake (K_i) on the second side, as calculated from values obtained at the first and last PET prior to surgery, was 0.00047. This rate of decrease closely agrees with that reported for a group of 32 non-operated patients with Parkinson's disease (0.00048; Morrish *et al.*, 1998). However, in patient 8, who exhibited a mild clinical response, there was a much more rapid decrease in putamenal fluorodopa uptake (annual decrease in $K_i = 0.00120$) compared with the others (ranging from 0.00005 in patient 7 to 0.00044 in patient 9). In patient 4 (Wenning *et al.*, 1997), who showed the most marked clinical effects, the annual rate of decrease of K_i in the non-grafted putamen was 0.00031.

Several conclusions can be inferred from the clinical data reported here. First, in patients with a previous graft leading to continuous functional improvement, a second contralateral graft implanted 10–56 months later can give rise to additional symptomatic relief. Secondly, the magnitude of improvement induced by the second graft in these patients seems less pronounced than that after the first implant. The percentage

Table 3 Characteristics of patients 1–10 grafted with embryonic mesencephalic tissue in Lund

Patient	Hoehn and Yahr**	Year of transplantation	Age (years)*	Duration of PD (years)*	Implantation site (no. of implants)*	No. of donors*	Clinical outcome†	Comments	References
1 (Lund)	4-5	1987	48	14	L put (2) + L caud (1)	4	1	Poor graft survival	Lindvall <i>et al.</i> , 1989
2 (Lund)	4	1987	55	14	R put (2) + R caud (1)	4	0.5	Poor graft survival	Lindvall <i>et al.</i> , 1989
3 (Lund)	3/2.5	1989/1993	48/53	12/17	L put (3)/R put (5)	4/5	2		Lindvall <i>et al.</i> , 1990 Lindvall <i>et al.</i> , 1992 Lindvall <i>et al.</i> , 1994 Wenning <i>et al.</i> , 1997; this report
4 (Lund)	3	1989	58	9	R put (3)	4	3		Lindvall <i>et al.</i> , 1992 Lindvall <i>et al.</i> , 1994 Wenning <i>et al.</i> , 1997
5 (San Jose)‡	4-5	1989	50	7	R put (3) + R caud (1)/ L put (3) + L caud (1)	4/4	2.5		Widner <i>et al.</i> , 1992
6 (San Jose)‡	4	1989	37	7	R put (3)/ L put (3) + L caud (1)	4/4	2.5		Widner <i>et al.</i> , 1992
7 (London)	2/2	1993/1994	49/50	10/11	L put (5)/R put (5)	5/5	2.5		Wenning <i>et al.</i> , 1997; this report
8 (London)	4/4	1993/1995	43/45	5/7	L put (4) + L caud (2)/ R put (5) + R caud (2)	5/8	1	Atypical parkinsonism	Wenning <i>et al.</i> , 1997; this report
9 (Lund)	4/4	1993/1994	52/53	10/11	L put (5)/R put (5)	4/7	1	Dementia	Wenning <i>et al.</i> , 1997; this report
10 (London)	4/2.5	1994/1994	42/43	9/10	R put (5) + R caud (2)/ L put (5)	7/4	2.5		Wenning <i>et al.</i> , 1997; this report

*For the first/second graft; **in practically defined off phase; †global improvement of parkinsonian symptoms after transplantation scored as follows: 0 = no improvement; 1 = clinically detectable graft effect of no or minor therapeutic value; 2 = clear graft effect of significant therapeutic value; 3 = marked improvement of major therapeutic value; ‡MPTP-induced parkinsonism. R = right, L = left, put = putamen, caud = caudate nucleus.

of time spent in the off phase, which decreased by ~50% in patients 3, 7 and 10 after the first transplantation, exhibited a further marked reduction in patients 7 and 10. However, the change in patient 3 was modest and transient. This is in agreement with the observation that no consistent alterations of the duration of the response to a single dose of L-dopa were observed in patient 3 after the second graft, in contrast to the lengthening of the response by ~1 h after the first implant. Patients 7 and 10, on the other hand, exhibited marked prolongation of the L-dopa response after both transplantations. The UPDRS motor score in the off phase decreased by 21, 18 and 9% after the second graft in patients 3, 7 and 10, respectively, compared with reductions of 25–46% after the first graft. Similarly, rigidity and movement speed in the contralateral arm during the off phase were less improved by the second than by the first graft. In this context, it is important to consider that the response to the second graft, especially with a long time lag between the sequential transplantations (as in patient 3), might be limited by changes in the patient's brain caused by the ongoing disease process. Thirdly, there is no evidence that the second graft jeopardized the function of the first. In patients 3, 7 and 10, no deterioration of any of the parameters that improved after the first transplantation could be detected after the second graft.

Pattern of functional effects after first and second grafts

A question of major interest is whether a second, contralateral graft leads to amelioration of parkinsonian symptoms that

are not improved by the first graft. In the present patient group, the unilateral striatal implants did not induce consistent improvements of gait, balance, posture, postural stability, swallowing or speech (Wenning *et al.*, 1997), which is in agreement with the findings of Defer and colleagues (Defer *et al.*, 1996). However, the second, contralateral transplantation did not give rise to any major, consistent improvements of these functions. This is in contrast to the observations in two cases with parkinsonism induced by MPTP (1-methyl-4-phenyl-1,2,3,6-tetrahydropyridine) (Widner *et al.*, 1992), who were grafted bilaterally in the putamen and uni- or bilaterally in the caudate nucleus, and who showed major improvement in gait, speech and balance after transplantation (Appendix). Furthermore, gait was improved in three out of four patients with idiopathic Parkinson's disease, who were grafted bilaterally in the postcommissural putamen in Tampa, FL, USA (Freeman *et al.*, 1995). It seems unlikely that the amelioration of these symptoms in the MPTP-treated patients was due to more efficient dopaminergic reinnervation of the striatum. The MPTP-treated patients received tissue from only three or four donors per side, at three sites in the putamen and one site in the caudate nucleus, and the restoration of fluorodopa uptake was similar to that observed in the present cases. It is therefore conceivable that the marked improvement of gait, speech and balance in the MPTP-treated patients (Widner *et al.*, 1992), as well as in individual cases with idiopathic Parkinson's disease (Defer *et al.*, 1996), is primarily explained by different patterns of dopaminergic denervation and possibly the lack of other brain pathology. However, the data of Freeman and colleagues

(Freeman *et al.*, 1995) suggest that adequate reinnervation of the postcommissural putamen bilaterally might be crucial for the improvement of gait.

Previous studies have indicated that intrastriatal mesencephalic grafts may influence drug-induced dyskinesias in parkinsonian patients (Widner *et al.*, 1992; Freeman *et al.*, 1995; Wenning *et al.*, 1997) and that the effects may vary depending on the interval after transplantation. In the present patient group, similarly to the developments after the first graft (Wenning *et al.*, 1997), there was a gradual increase in the duration of the L-dopa response during the early phase after the second transplantation. Consequently, on-time with dyskinesias increased, necessitating a reduction of the daily L-dopa dose in patients 7, 9 and 10. It is conceivable that during this early phase the grafts are immature, and have not formed any major synaptic connections with host striatal neurons. In the later phase, patients 7 and 10 had decreased their on-time with dyskinesias, and showed gradually reduced fluctuations and improved parkinsonism despite no further major drug changes. The course was less favourable for patient 3, who, following the enforced bromocriptine withdrawal, developed dystonias that the grafts could not alleviate. In patient 9, the on-time with dyskinesias was reduced, but the off-time increased in parallel. Beneficial effects in the late phase may reflect maturation of grafted dopamine neurons associated with sufficient reinnervation of the host brain and partial normalization of postsynaptic receptors.

General discussion

In addition to the five cases described here, we have previously reported major improvements after unilateral grafting in another patient in the same series (patient 4) (Wenning *et al.*, 1997; Appendix), whose recovery had been such that he did not feel the need for a second graft. Thus, in this series, four out of five patients with idiopathic Parkinson's disease (excluding patient 8 with possible multiple system atrophy), grafted unilaterally or bilaterally, have exhibited marked symptomatic relief and two of them have been able to withdraw L-dopa treatment. Patient 4 restarted L-dopa (200 mg controlled release daily) after 3.5 years due to slight symptom progression on the side contralateral to the non-grafted putamen, while patient 7 at the time of this report (3.5 years after withdrawal) still is without L-dopa. Our findings show that implantation of embryonic mesencephalic tissue can give rise to long-lasting improvement of therapeutic value in the majority of patients.

In order to improve the clinical outcome of neural grafting in Parkinson's disease and to make this approach accessible to a larger number of patients, dopamine neuron survival after transplantation has to be increased. In the present cases, tissue from a total of 9–13 human embryonic donors was used in each patient (four to seven donors on the first side and four to eight on the second side). One possible way of

reducing the need for human embryonic tissue is to administer compounds promoting neuronal survival. These include lazaroids, a group of compounds which inhibit lipid peroxidation elicited by free radical stress and increase dopamine neuron survival *in vitro* and in rats *in vivo* about two-fold (Frodj *et al.*, 1994; Nakao *et al.*, 1994; Othberg *et al.*, 1997; Bjorklund *et al.*, 1997). Also, caspase inhibitors, which counteract apoptosis and have recently been shown to enhance nigral graft survival about four-fold (Schierle *et al.*, 1999). Another way of obtaining large amounts of embryonic mesencephalic tissue could be to use xenografts. However, in the initial attempts with porcine xenografts in patients, the survival of dopamine neurons has been poor and the clinical benefits are as yet uncertain (Deacon *et al.*, 1997). Finally, recent data (Studer *et al.*, 1998) suggest that dopamine neurons expanded from stem cells obtained from small quantities of early embryonic tissue might become useful for transplantations in patients with Parkinson's disease.

Even though the present findings show that bilateral grafts give rise to more pronounced symptomatic relief than unilateral grafts, the improvement is still incomplete and varies among patients. The degree of graft-derived reinnervation of the putamen, as revealed by the restoration of fluorodopa uptake, appears to determine the magnitude of improvement of motor function. Dopaminergic reinnervation of the putamen is incomplete with present transplantation procedures. Histopathological analysis in two parkinsonian patients showed 30–80% reinnervation of the post-commissural putamen, in which six to eight implantation tracts were localized, whereas the graft-derived reinnervation of the anterior putamen was extremely sparse (Kordower *et al.*, 1995, 1996, 1998). It seems highly likely that the present patients and those operated on by the French group (Peschanski *et al.*, 1994; Defer *et al.*, 1996), in whom three to five implantation tracts were distributed over the entire putamen, also have incomplete reinnervation of this structure. Therefore, one major strategy for the improvement of functional recovery in operated patients should be to develop procedures that more completely reinnervate all parts of the putamen. In addition, a detailed, and possibly repeated, preoperative analysis of the pattern and degree of dopaminergic denervation, performed using high-resolution imaging techniques, seems highly warranted for patient selection and to determine the amount of tissue and the number and location of implantation sites required to obtain optimal reinnervation.

Acknowledgements

We thank the patients and their families for their co-operation, A. Othberg and H. Edvall for technical assistance and M. Lundin for secretarial work. This work was supported by grants from the Swedish Medical Research Council, the UK Medical Research Council, The Bank of Sweden Tercentenary

Foundation, the UK Parkinson's Disease Society, the Kock Foundation, the Wiberg Foundation, the Soderberg Foundation, the Wellcome Trust, the European Union (Biomed grant BMH4-CT95-0341) and the Medical Faculty, University of Lund, Sweden.

References

- Bjorklund L, Spenger C, Stromberg I. Tirilazad mesylate increases dopaminergic neuronal survival in the *in oculo* grafting model. *Exp Neurol* 1997; 148: 324–33.
- Deacon T, Schumacher J, Dinsmore J, Thomas C, Palmer P, Kott S, et al. Histological evidence of fetal pig neural cell survival after transplantation into a patient with Parkinson's disease. *Nat Med* 1997; 3: 350–3.
- Defer GL, Geny C, Ricolfi F, Fenelon G, Monfort JC, Remy P, et al. Long-term outcome of unilaterally transplanted parkinsonian patients: I. Clinical approach. *Brain* 1996; 119: 41–50.
- Duan WM, Widner H, Bjorklund A, Brundin P. Sequential intrastriatal grafting of allogeneic embryonic dopamine-rich neuronal tissue in adult rats: will the second graft be rejected? *Neuroscience* 1993; 57: 261–74.
- Freeman TB, Olanow CW, Hauser RA, Nauert GM, Smith DA, Borlongan CV, et al. Bilateral fetal nigral transplantation into the postcommissural putamen in Parkinson's disease. *Ann Neurol* 1995; 38: 379–88.
- Frodl EM, Nakao N, Brundin P. Lazaroids improve the survival of cultured rat embryonic mesencephalic neurones. *Neuroreport* 1994; 5: 2393–6.
- Gibb WR, Lees AJ. The relevance of the Lewy body to the pathogenesis of idiopathic Parkinson's disease. [Review]. *J Neurol Neurosurg Psychiatry* 1988; 51: 745–52.
- Kordower JH, Freeman TB, Snow BJ, Vingerhoets FJ, Mufson EJ, Sanberg PR, et al. Neuropathological evidence of graft survival and striatal reinnervation after the transplantation of fetal mesencephalic tissue in a patient with Parkinson's disease [see comments]. *N Engl J Med* 1995; 332: 1118–24. Comment in: *N Engl J Med* 1995; 332: 1163–4, Comment in: *N Engl J Med* 1995; 333: 730–1.
- Kordower JH, Rosenstein JM, Collier TJ, Burke MA, Chen EY, Li JM, et al. Functional fetal nigral grafts in a patient with Parkinson's disease: chemoanatomic, ultrastructural, and metabolic studies. *J Comp Neurol* 1996; 370: 203–30.
- Kordower JH, Styren S, Clarke M, DeKosky T, Olanow CW, Freeman TB. Fetal grafting for Parkinson's disease: expression of immune markers in two patients with functional fetal nigral implants. *Cell Transplant* 1997; 6: 213–19.
- Kordower JH, Freeman TB, Chen EY, Mufson EJ, Sanberg PR, Hauser RA, et al. Fetal nigral grafts survive and mediate clinical benefit in a patient with Parkinson's disease. *Mov Disord* 1998; 13: 383–93.
- Langston JW, Widner H, Goetz CG, Brooks D, Fahn S, Freeman T, et al. Core assessment program for intracerebral transplantations (CAPIT). *Mov Disord* 1992; 7: 2–13.
- Lindvall O, Rehncrona S, Brundin P, Gustavii B, Åstedt B, Widner H, et al. Human fetal dopamine neurons grafted into the striatum in two patients with severe Parkinson's disease: a detailed account of methodology and a 6-month follow-up. *Arch Neurol* 1989; 46: 615–31.
- Lindvall O, Brundin P, Widner H, Rehncrona S, Gustavii B, Frackowiak R, et al. Grafts of fetal dopamine neurons survive and improve motor function in Parkinson's disease [see comments]. *Science* 1990; 247: 574–77. Comment in: *Science* 1990; 247: 529.
- Lindvall O, Widner H, Rehncrona S, Brundin P, Odin P, Gustavii B, et al. Transplantation of fetal dopamine neurons in Parkinson's disease: one-year clinical and neurophysiological observations in two patients with putaminal implants. *Ann Neurol* 1992; 31: 155–65.
- Lindvall O, Sawle G, Widner H, Rothwell JC, Bjorklund A, Brooks D, et al. Evidence for long-term survival and function of dopaminergic grafts in progressive Parkinson's disease. *Ann Neurol* 1994; 35: 172–80.
- Morrish PK, Rakshi JS, Bailey DL, Sawle GV, Brooks DJ. Measuring the rate of progression and estimating the preclinical period of Parkinson's disease with [¹⁸F]dopa PET. *J Neurol Neurosurg Psychiatry* 1998; 64: 314–9.
- Nakao N, Frodl EM, Duan WM, Widner H, Brundin P. Lazaroids improve the survival of grafted rat embryonic dopamine neurons. *Proc Natl Acad Sci USA* 1994; 91: 12408–12.
- Othberg A, Keep M, Brundin P, Lindvall O. Tirilazad mesylate improves survival of rat and human embryonic mesencephalic neurons *in vitro*. *Exp Neurol* 1997; 147: 498–502.
- Peschanski M, Defer G, N'Guyen JP, Ricolfi F, Monfort JC, Remy P, et al. Bilateral motor improvement and alteration of L-dopa effect in two patients with Parkinson's disease following intrastriatal transplantation of foetal ventral mesencephalon. *Brain* 1994; 117: 487–99.
- Rehncrona S. A critical review of the current status and possible developments in brain transplantation. [Review]. *Adv Tech Stand Neurosurg* 1997; 23: 3–46.
- Remy P, Samson Y, Hantraye P, Fontaine A, Defer G, Mangin JF, et al. Clinical correlates of [¹⁸F] fluorodopa uptake in five grafted parkinsonian patients. *Ann Neurol* 1995; 38: 580–8.
- Sawle GV, Bloomfield PM, Bjorklund A, Brooks DJ, Brundin P, Leenders KL, et al. Transplantation of fetal dopamine neurons in Parkinson's disease: PET [¹⁸F]-6-L-fluorodopa studies in two patients with putaminal implants. *Ann Neurol* 1992; 31: 166–73.
- Schierle GS, Hansson O, Leist M, Nicotera P, Widner H, Brundin P. Caspase inhibition reduces apoptosis and increases survival of nigral transplants. *Nat Med* 1999; 5: 97–100.
- Studer L, Tabar V, McKay RDG. Transplantation of expanded mesencephalic precursors leads to recovery in parkinsonian rats. *Nat Neurosci* 1998; 1: 290–5.
- Wenning GK, Odin P, Morrish P, Rehncrona S, Widner H, Brundin P, et al. Short- and long-term survival and function of unilateral intrastriatal dopaminergic grafts in Parkinson's disease. *Ann Neurol* 1997; 42: 95–107.

Widner H, Brundin P. Sequential intracerebral transplantation of allogeneic and syngeneic fetal dopamine-rich neuronal tissue in adult rats: will the first graft be rejected? *Cell Transplant* 1993; 2: 307–17.

Widner H, Tetrad J, Rehnrona S, Snow B, Brundin P, Gustavii B, et al. Bilateral fetal mesencephalic grafting in two patients with

parkinsonism induced by 1-methyl-4-phenyl-1,2,3,6-tetrahydropyridine (MPTP) [see comments]. *N Engl J Med* 1992; 327: 1556–63. Comment in: *N Engl J Med* 1992; 327: 1589–92.

Received September 7, 1998. Revised December 12, 1998. Accepted January 26, 1999

Appendix

We have previously reported 10 patients subjected to unilateral or bilateral, intrastriatal transplantation of embryonic mesencephalic tissue at the University Hospital, Lund, Sweden. The outcome after sequential bilateral grafts in patients 3 and 7–10 is described in the main text of this paper. The clinical course of patients 1, 2 and 4–6 is summarized below, and the characteristics of all 10 patients are given in Table 3.

Patients 1 and 2. These patients were grafted unilaterally in the putamen and caudate nucleus (Table 3). Postoperative clinical benefit was modest and PET did not show any significant changes of fluorodopa uptake 5–6 months after surgery. Except for a slight improvement of gait in patient 1, no long-term graft effects have been observed. The poor graft survival in these patients was probably mainly due to loss of tissue during its preparation and the large diameter of the implantation cannula (2.5 mm compared with 1.0 mm in subsequent patients).

Patient 4. This patient was grafted unilaterally in the putamen (Table 3). From 4 months postoperatively he showed a gradual, major clinical improvement. During the second year after transplantation, rigidity and hypokinesia were markedly reduced bilaterally, but predominantly contralaterally to the graft. On–off fluctuations disappeared and L-dopa could be withdrawn after 32 months. Low-dose L-dopa (200 mg controlled release, compared with 450 mg standard preoperatively) was reintroduced 3.5 years later (i.e. 74 months after surgery) due to slight progression of symptoms on the side ipsilateral to the graft as well as axially. He responded well to medication, and motor function and L-dopa dose have since been

unchanged. At present (9.5 years after transplantation), he exhibits continuous marked benefit with no rigidity, minor hypokinesia, intermittent mild resting tremor and no motor fluctuations. The latest PET scan (6 years after transplantation) showed that fluorodopa uptake in the grafted putamen had reached a level equivalent to that in normal subjects.

Patient 5. This patient has MPTP-induced parkinsonism and was grafted bilaterally in the putamen and caudate nucleus (Table 3). After a delay of 9–12 months, there was a progressive improvement of rigidity, hypokinesia, freezing, balance, swallowing and speech, and the time spent in the on phase increased. Dyskinesias induced by L-dopa were dramatically reduced. Twenty-four months after surgery, PET showed a significant increase in striatal fluorodopa uptake bilaterally. This patient still experiences clear improvement of motor function 9 years postoperatively but suffers from hallucinations and depression, which were also present preoperatively. These symptoms have persisted despite periodic, complete L-dopa withdrawal and trials with clozapine and antidepressants.

Patient 6. This patient has MPTP-induced parkinsonism. She was grafted bilaterally in the putamen and unilaterally in the caudate nucleus (Table 3), and showed marked symptomatic relief starting 6 months after surgery. During the second postoperative year, rigidity virtually disappeared and hypokinesia, balance, speech and gait were clearly improved. Dyskinesias were dramatically reduced and the time in the on phase increased. The L-dopa dose was reduced by 70%. PET showed a significant, bilateral increase in striatal fluorodopa uptake 22 months after surgery. Since then her antiparkinsonian medication has been unchanged, and she has only minor motor problems and lives an independent life.